



THE AMERICAN SOCIETY OF
EMERGENCY RADIOLOGY

Looking for More Than Gas: Fournier's Gangrene, *A Contemporary Update*

Mohammad Haroon¹, Sirote Wongwaisayawan¹, Yashmin Nisha¹, Nicola Schieda¹,
Satheesh Krishna Jeyaraj², Paul Sathiadoss¹, Sabarish Narayanasamy³, Adnan Sheikh¹

¹University of Ottawa – The Ottawa Hospital, Ottawa, ON, Canada; ²University of Toronto, Toronto, ON, Canada;

³The University of Iowa, Iowa City, IA, United States

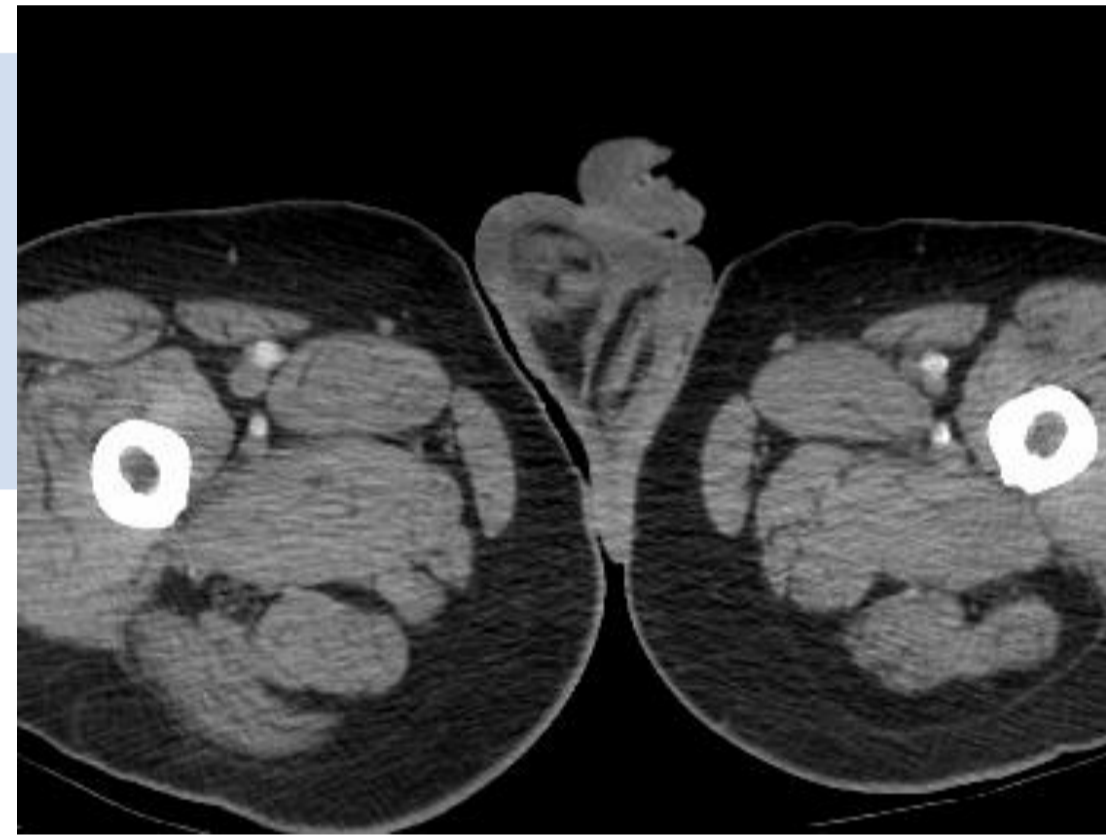
Neither I nor my immediate family members have a financial relationship with a commercial organization that may have a direct or indirect interest in the content

Target audiences: Radiologists, emergency physicians and surgeons

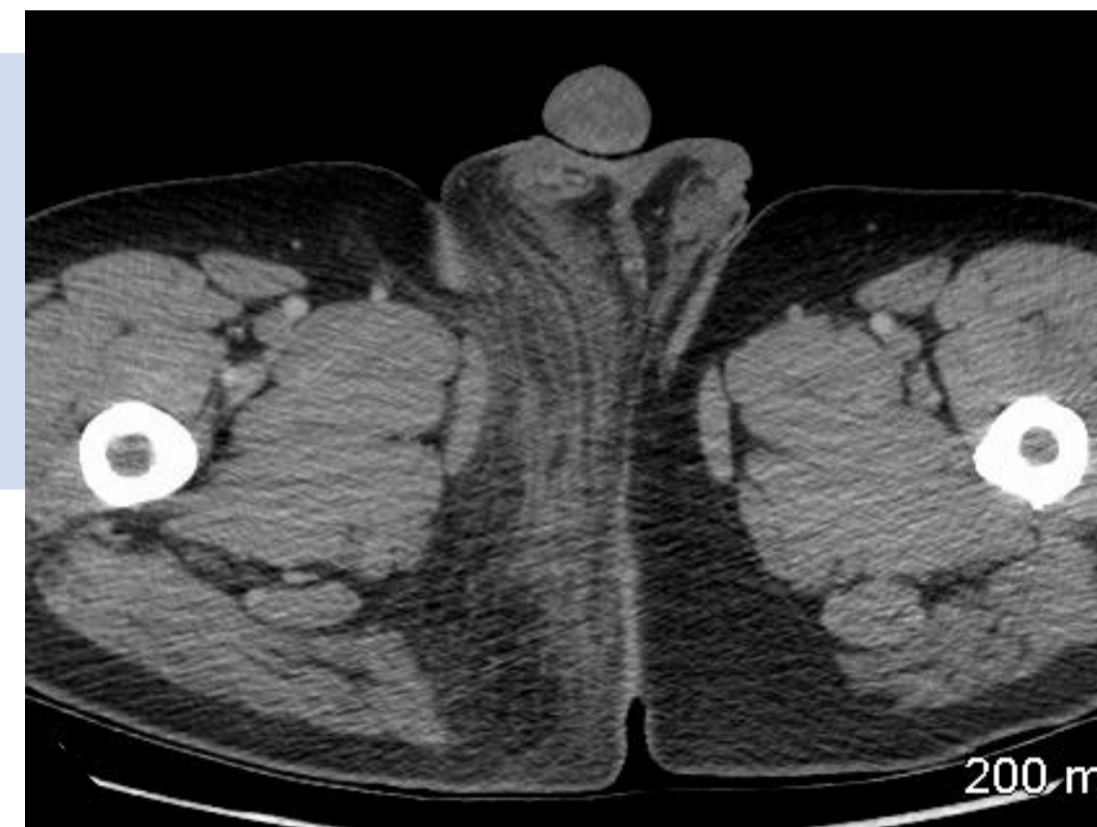Goals and Objectives:

- Familiarize audiences with many imaging appearances of Fournier's gangrene
- Demonstrate underlying causes and predisposing conditions with help of CT

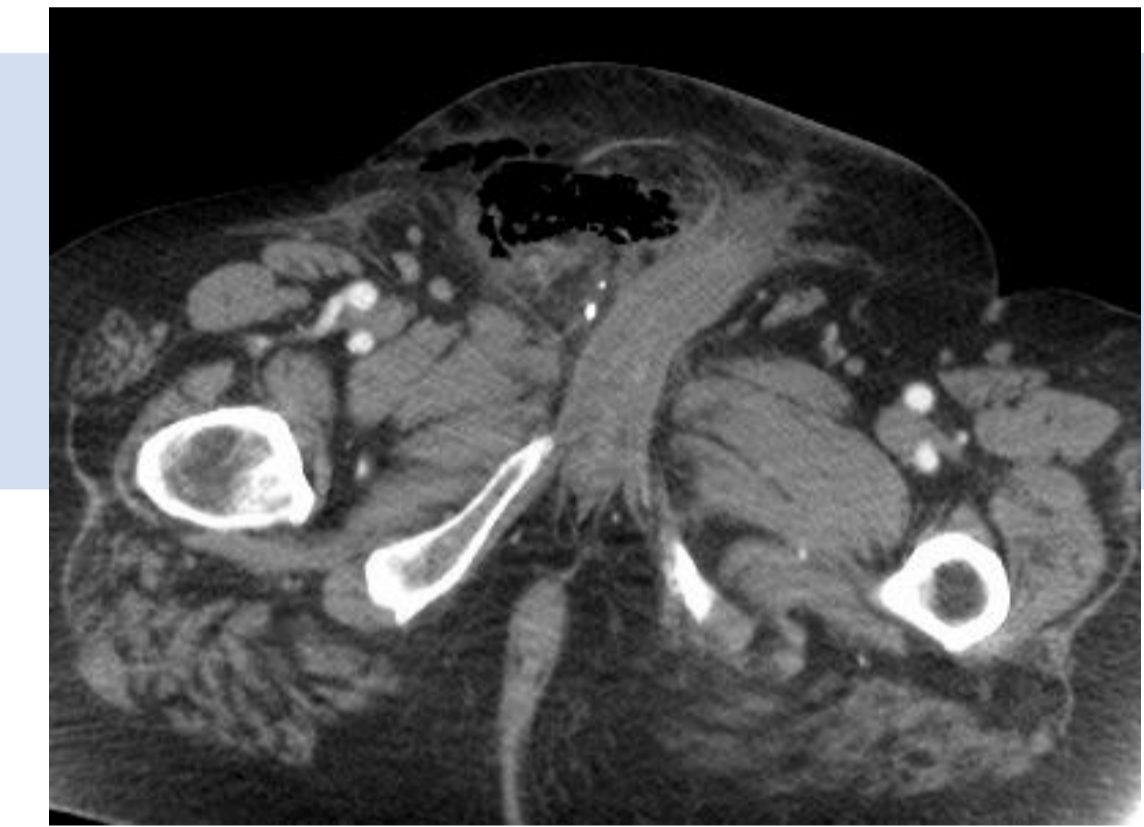
“Rapidly progressing **NECROTIZING FASCIITIS** of the **perineal**, **perianal** and **genital** region”



CELLULITIS



FASCIITIS



SOFT TISSUE GAS

INSTRUMENTATION
IMMUNOCOMPROMISED
ALCOHOL DM
MALE
OBESITY

RISK FACTOR

PATHOGEN PSEUDOMONAS
STAPHYLOCOCCUS
STREPTOCOCCAL ANAEROBE
ESCHERICHIA COLI
BACTEROIDES KLEBSIELLA
ENTEROCOCCUS
CLOSTRIDIUM PROTEUS

PATHOGEN

NEUROGENIC EPIDIDYMITIS
PERFORATION
COLONIC ABSCESS
UTI PERIRECTAL PERIANAL
UROLOGIC FISSURE ANAL
STRICTURE URETHRAL
BLADDER

ETIOLOGY

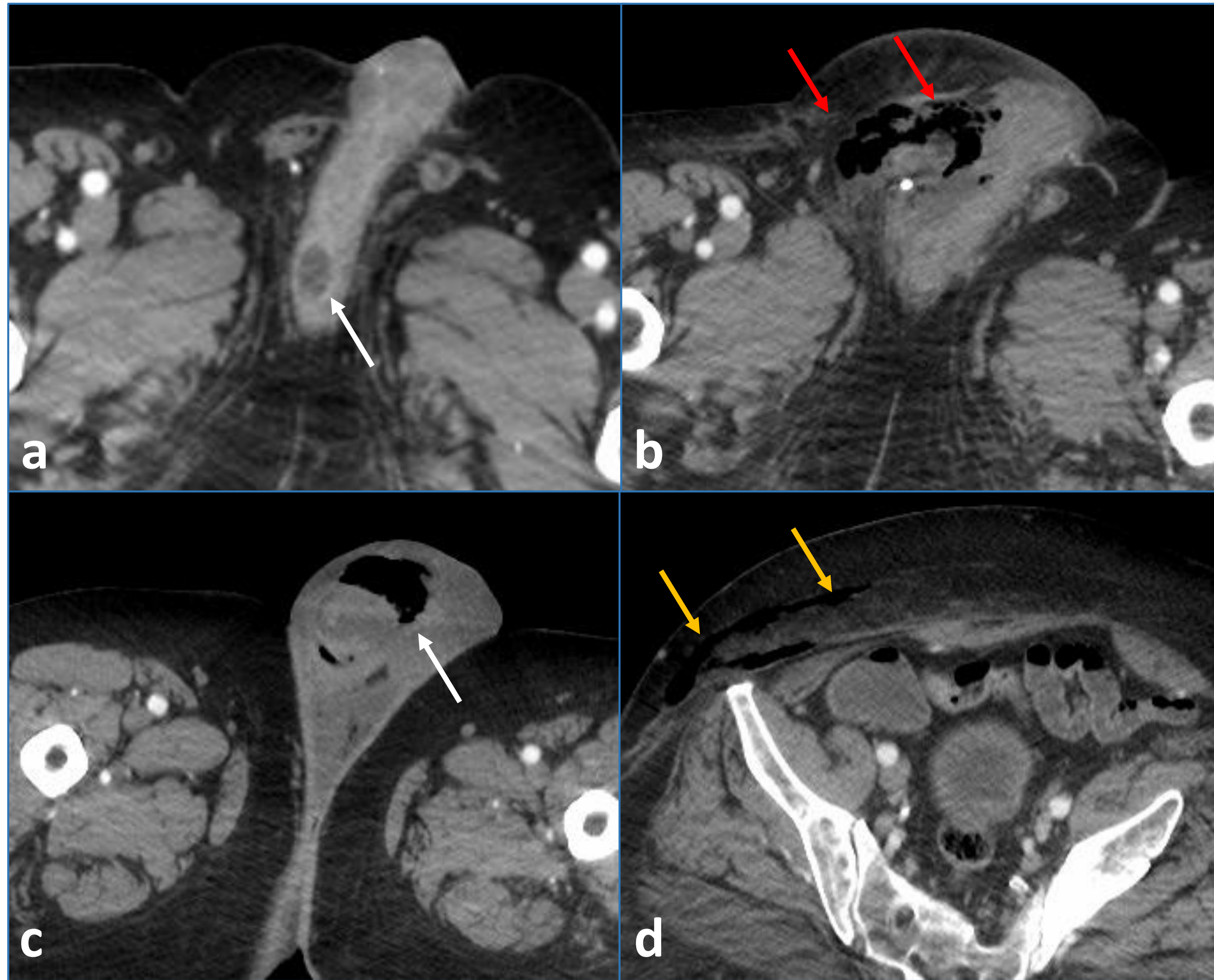


Fig 1. Fournier's gangrene with penoscrotal abscess. **a** axial CT image shows a small abscess at penoscrotal junction (**arrow**). **b** axial CT image of same patient obtained 3 months later shows progression into Fournier's gangrene (**red arrow**). **c, d** axial CT images at different section show bilateral scrotal edema with soft tissue gas along right hemiscrotum (**arrow**) and along abdominal wall (**yellow arrow**).

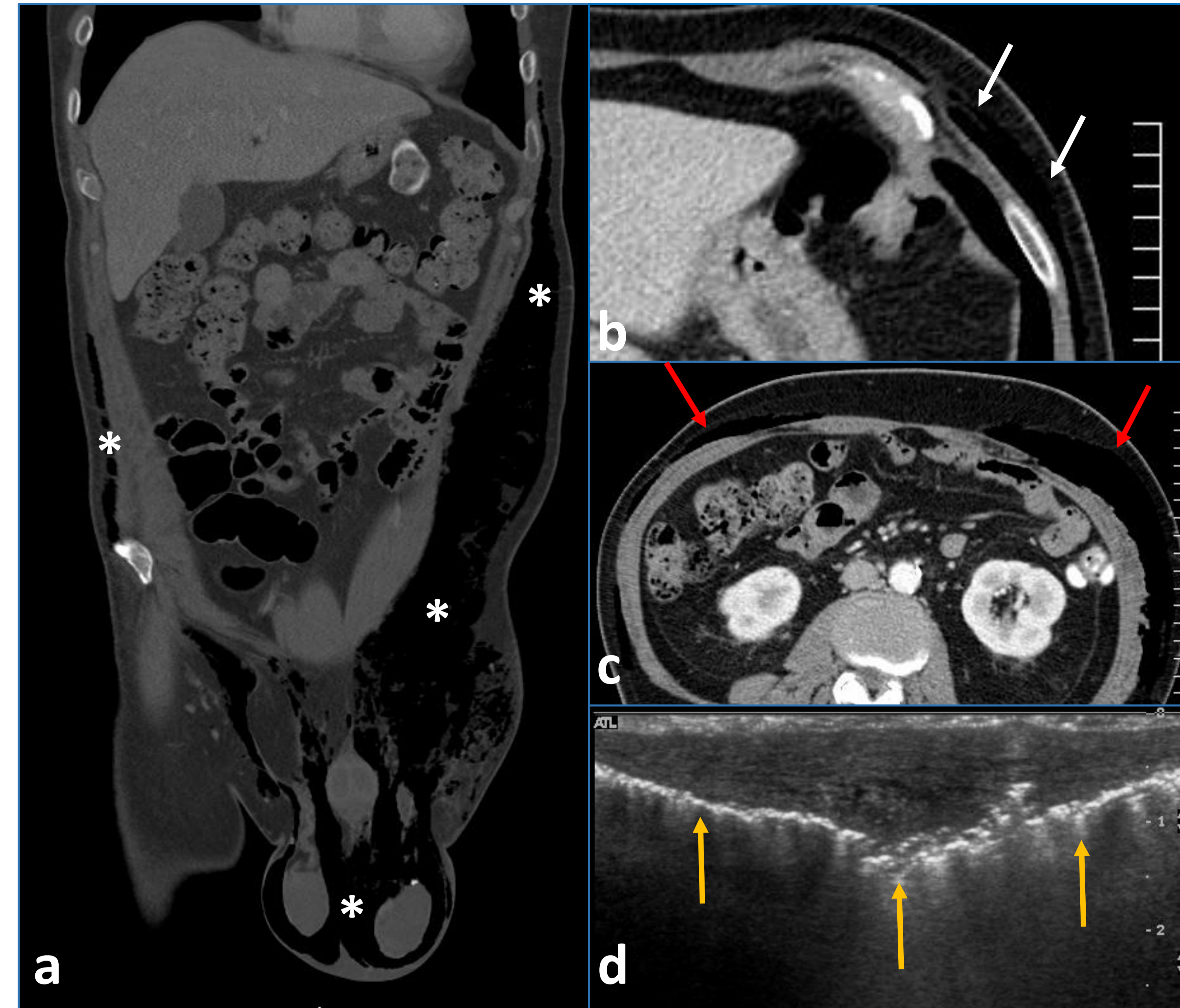


Fig 2. Fournier's gangrene with extensive spread to chest wall. **a** coronal CT image shows extensive spread of soft tissue gas involving scrotum, inguinal area, perineum, anterior abdominal wall up to left anterior chest wall (*). **b, c** axial CT images demonstrate soft tissue gas along left anterior chest wall (**arrow**) and abdominal wall (**red arrow**). **d** US image at left inguinal area shows soft tissue edema with extensive soft tissue gas (**yellow arrow**).

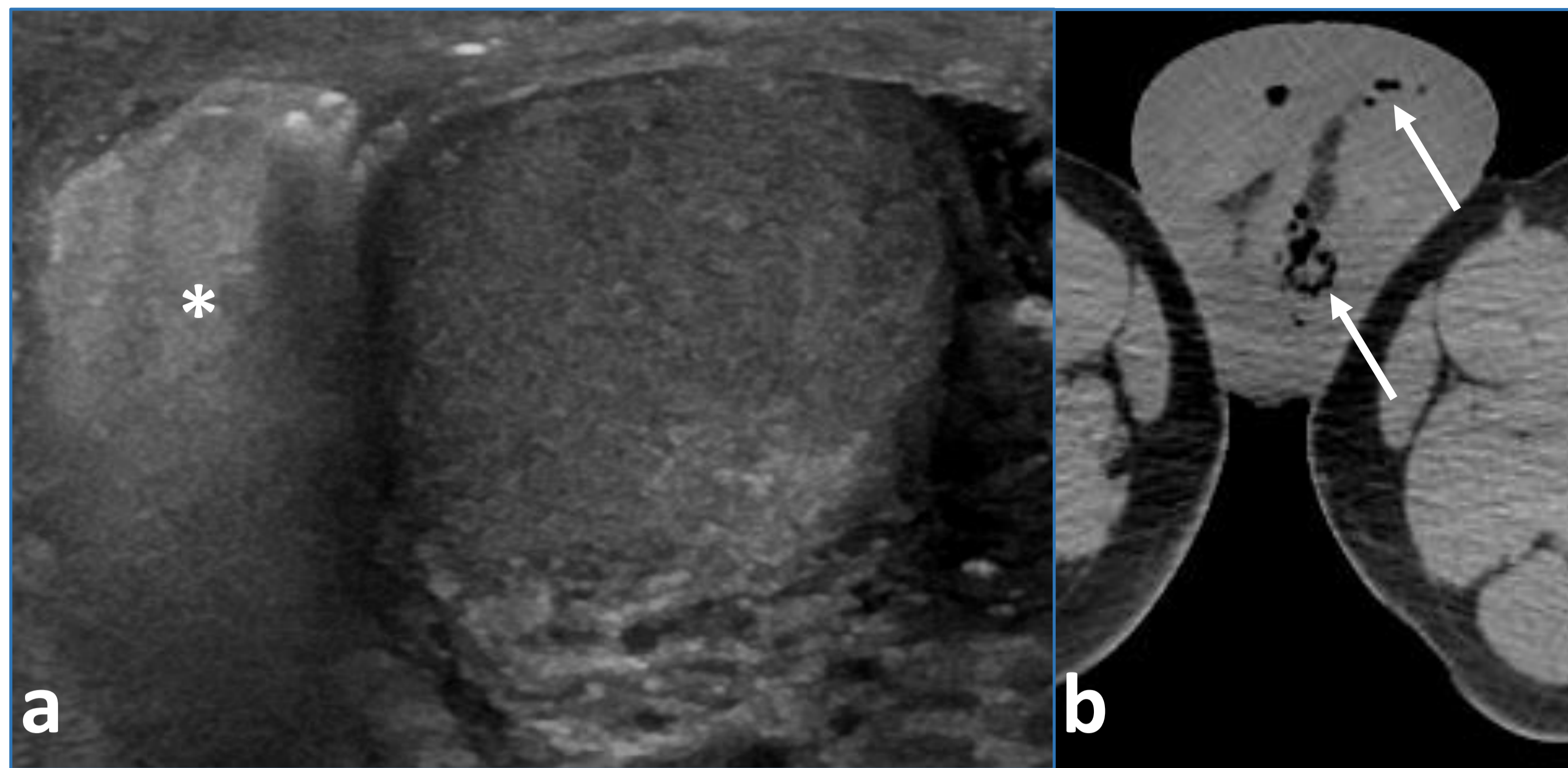


Fig 3. Fournier's gangrene with scrotal involvement. a. US image shows scrotal wall edema with soft tissue gas (*). b axial CT image confirms US findings of bilateral scrotal edema and soft tissue gas (arrow).

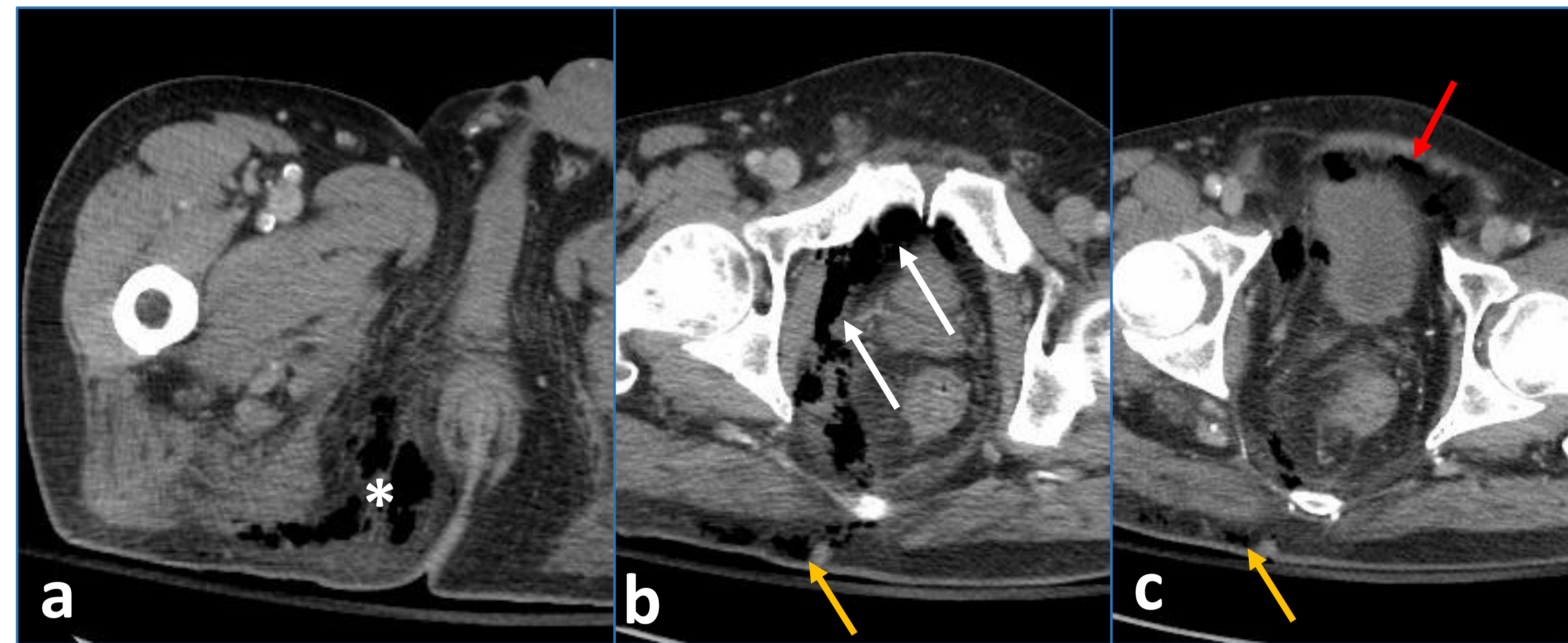


Fig 4. Fournier's gangrene with extraperitoneal spread. a, b and c axial CT images show fat stranding and soft tissue gas at right ischioanal fossa (*) with extension to prevesical space and perivesical space (arrow), extraperitoneal space (red arrow) and buttock (yellow arrow).

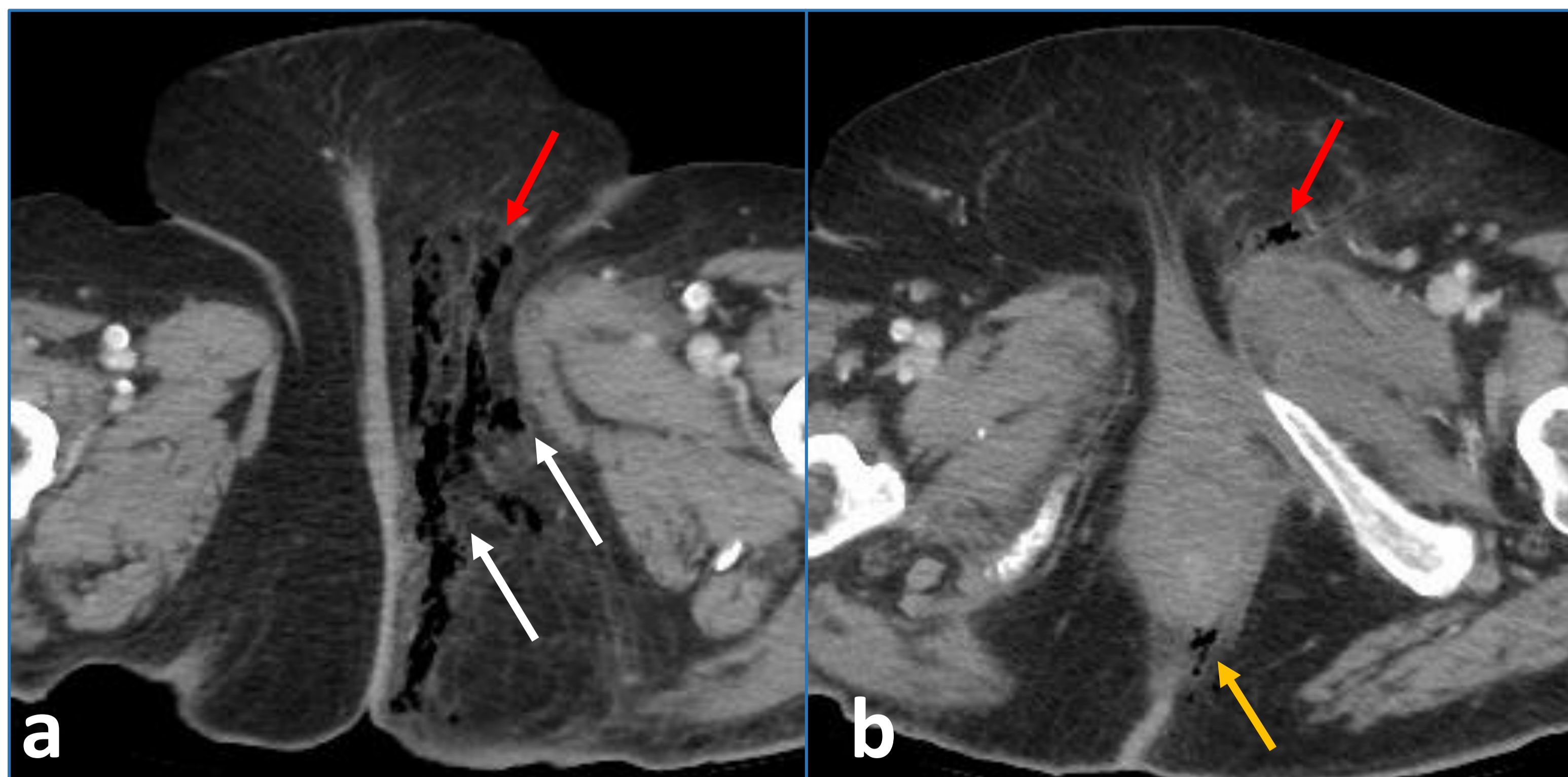


Fig 5. Fournier's gangrene in female. a, b axial CT images show fat stranding and soft tissue gas at left-sided perineum (arrow) with extension to left labia majora (red arrow) and left ischioanal fossa (yellow arrow).

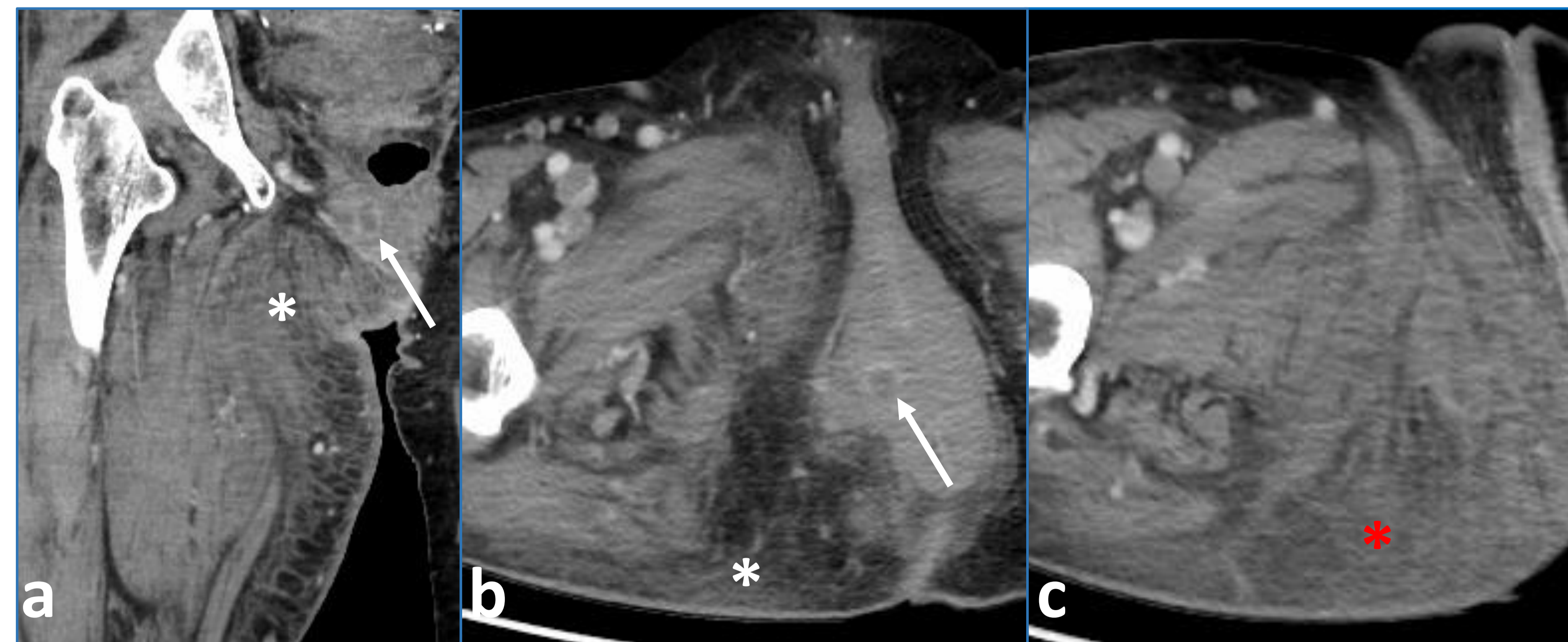


Fig 6. Fournier's gangrene in female. a, b coronal and axial CT images show a small periurethral abscess (arrow) with extensive fat stranding along right-sided perineum and right buttock (*). c axial CT image at lower section also shows extensive fat stranding at medial thigh (*).



THE AMERICAN SOCIETY OF
EMERGENCY RADIOLOGY

Thank You Very Much

Mohammad Haroon: haroon.radiology@gmail.com

Sirote Wongwaisayawan: srww386@hotmail.com

University of Ottawa – The Ottawa Hospital
501 Smyth Road, Ottawa, Ontario, Canada K1H 8L6

Suggested readings:

- Levenson RB, Singh AK, Novelline RA. Fournier gangrene: role of imaging. *Radiographics* 2008;28(2):519-528
- Chennamsetty A, Khourdaji I, Burks F, Killinger KA. Contemporary diagnosis and management of Fournier's gangrene. *Ther Adv Urol* 2015;7(4):203-215
- Ioannidis O, Kitsikosta L, Tatsis D, et al. Fournier's Gangrene: lessons learned from multimodal and multidisciplinary management of perineal necrotizing fasciitis. *Front Surg* 2017;4:36