



THE AMERICAN SOCIETY OF
EMERGENCY RADIOLOGY

GAS PRODUCING INFECTIONS OF ABDOMEN AND PELVIS: A PICTORIAL REVIEW

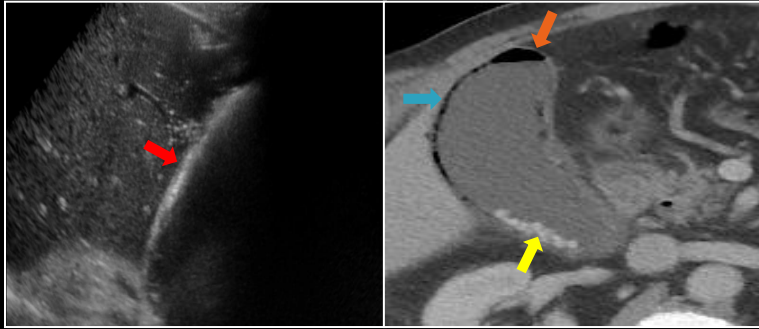
Mohammad Haroon , Yashmin Nisha, Sathiadoss Paul, Satheesh Krishna, Kashif Iqbal, Sabarish Narayansamy, Abhishek Jha, Gaurav Raj, Adnan Sheikh

Goals and Objectives: Recognize the imaging features of the spectrum of various commonly encountered emphysematous infections of the abdomen and pelvis and their mimics

Target audience: Residents, Fellows, Emergency Radiologists and Physicians.

Disclosure: None of the authors or their immediate family members have a financial relationship with a commercial organization that may have direct or indirect interest in the content

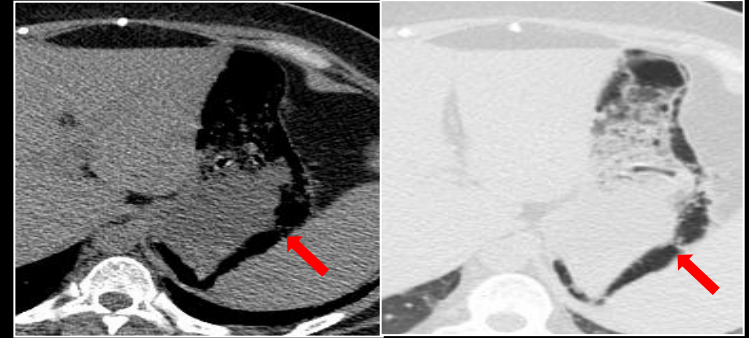
EMPHYSEMATOUS CHOLECYSTITIS



Reverberation artifacts

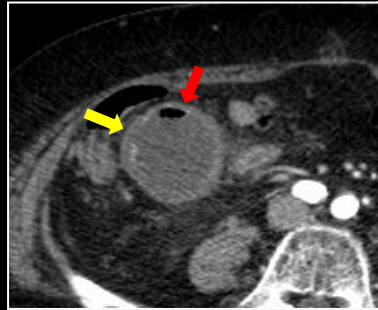
Intramural gas, Intraluminal gas, calculi

EMPHYSEMATOUS GASTRITIS



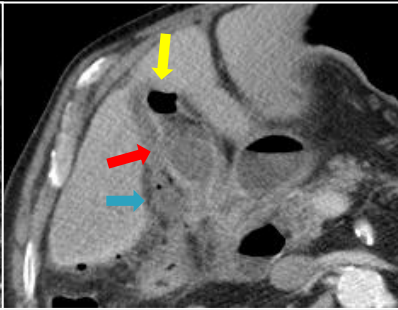
Nodular and irregular collections of gas within the stomach wall

Gangrene without perforation



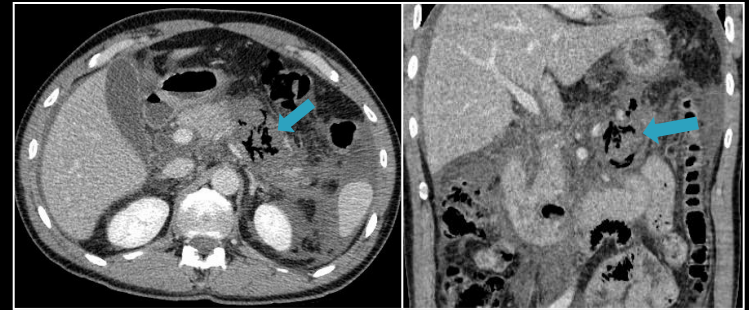
Gangrenous area
Intraluminal air locule

Gangrene with perforation



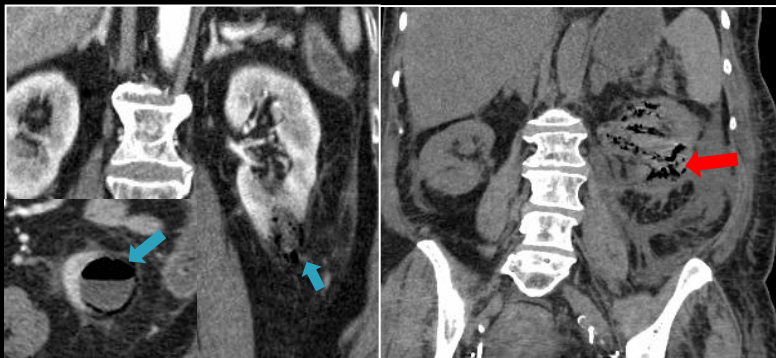Focal perforation
Intraluminal air locule
Pericholecystic collection

EMPHYSEMATOUS PANCREATITIS



Air within the necrotic pancreas

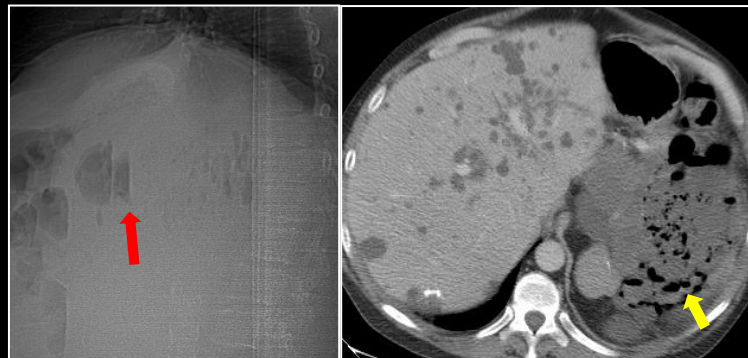
EMPHYSEMATOUS PYELONEPHRITIS



Emphysematous infection of renal cyst

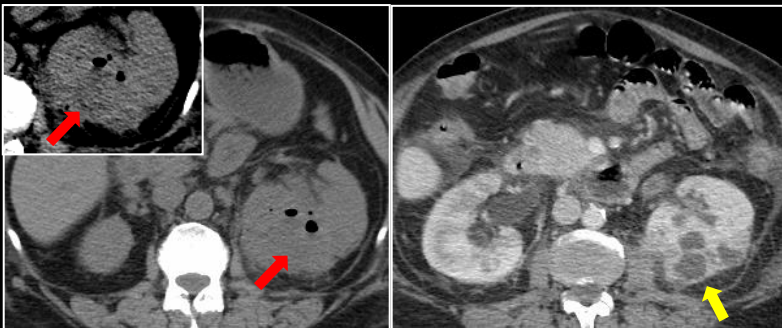
Type I Emphysematous PN: Streaky mottled gas collection

EMPHYSEMATOUS PYELONEPHRITIS

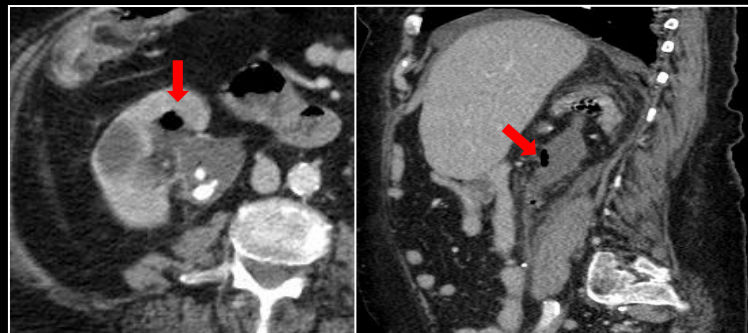


Emphysematous PN in ADPKD: Air-fluid levels, Gas locules in cysts

EMPHYSEMATOUS PYELITIS

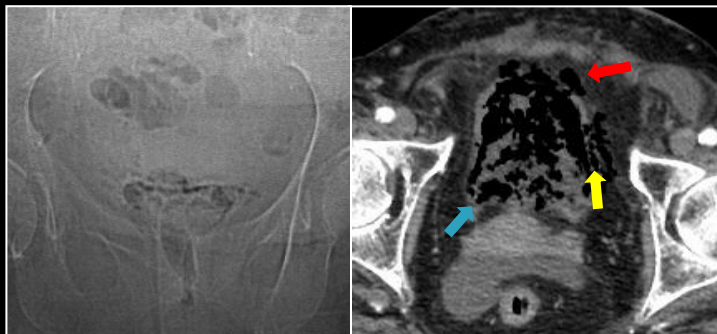


Type II Emphysematous PN: Gas with collections, abscesses

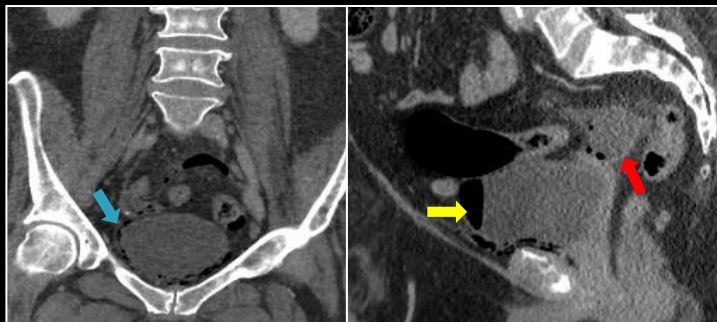


Emphysematous Pyelitis: Gas in collecting system

EMPHYSEMATOUS CYSTITIS

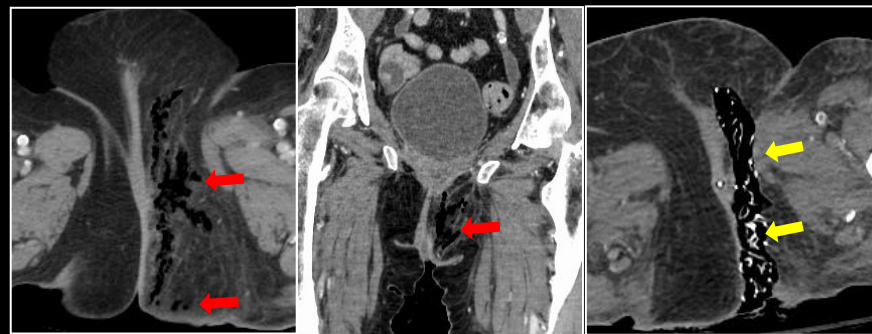


Intraluminal, intramural, extravesical gas

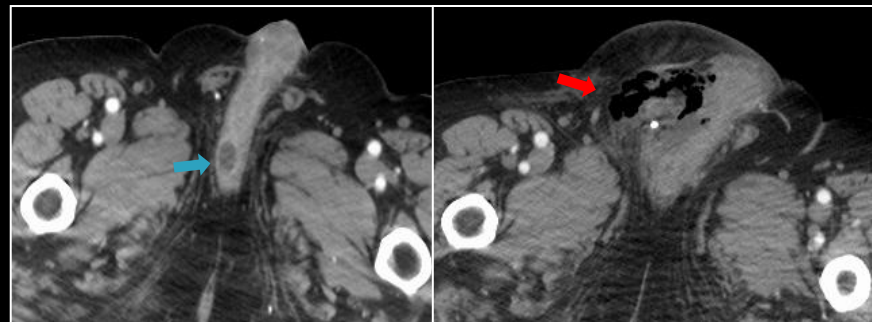


Intraluminal, intramural gas, gas containing collection in cul de sac with extravesical gas

FOURNIER GANGRENE (FG)

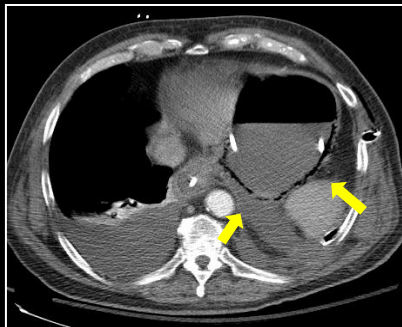


Vulval and perineal involvement, Post debridement

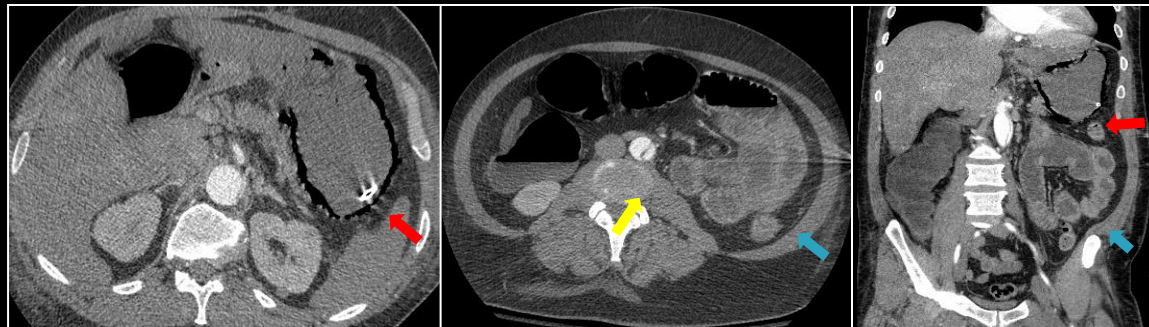


Penile root abscess & evolution into FG

MIMICS



Benign Gastric Emphysema



Ischemic gastric pneumatosis, Ischemic bowels, Dissection flap

SUGGESTED READING: Grayson DE, Abbott RM, Levy AD, Sherman PM. Emphysematous Infections of the Abdomen and Pelvis: A Pictorial Review. Radiographics. 2002 May-Jun;22(3):543-61.

Mohammad Haroon
Clinical Fellow,
The Ottawa Hospital,
University of Ottawa,
501, Smyth Road, Ottawa, K1H 8L6
Email: haroon.radiology@gmail.com