

# Sacral Fractures: Demystifying AO Spine Sacral Classification System

Naga Ramesh Chinapuvvula MD,  
Bawa Pritish MD, Patel Rajan MD,  
Beckmann Nicholas MD, Suresh Cheekatla MD,



UTHealth®

The University of Texas  
Health Science Center at Houston

McGovern  
Medical School

Authors have no disclosures

# AO Spine Sacral Classification System

## Type A: Lower Sacro-coccygeal

- **A1**- Coccygeal or compression vs ligamentous avulsion injuries
- **A2**- Non-displaced transverse fractures below the SI joint
- **A3**- Displaced transverse fractures below the SI joint

## Type B: Posterior Pelvic

- **B1**- Central fracture-involves spinal canal
- **B2**- Transalar fracture-does not involve the foramina or spinal canal
- **B3**- Transforaminal fracture involves the foramina but not spinal canal

## Type C: Spino-Pelvic

- **C0**- Non-displaced sacral U-type variant
- **C1**- Alternative Sacral U-type variant without posterior pelvic instability
- **C2**- Bilateral complete Type B injuries without transverse fracture
- **C3**- Displaced U-type fracture

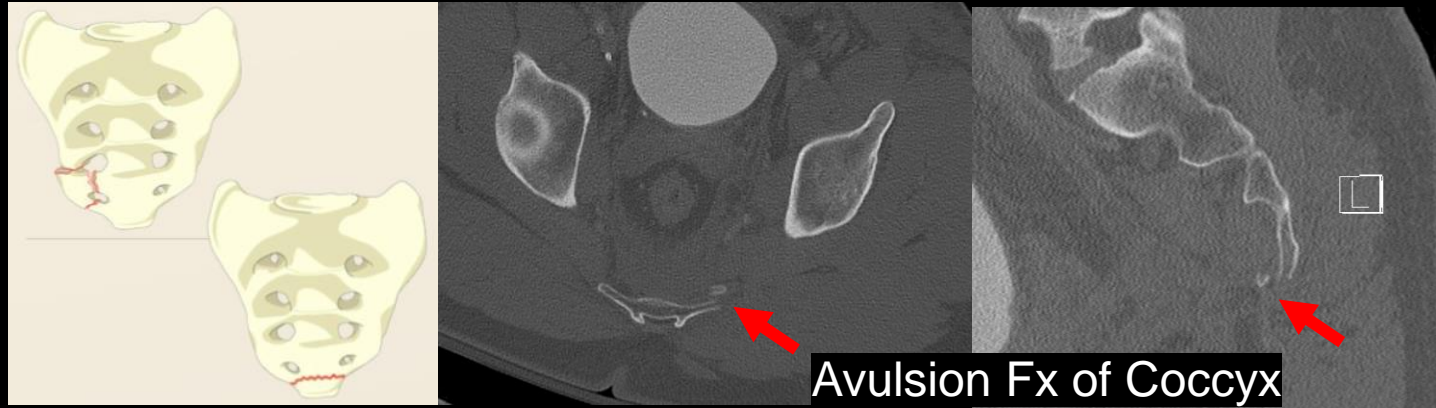
- **Neurological status modifier**
- **Case-specific modifiers**

References: 1. AOSpine Injury Classification-AO Foundation <https://aofoundation.org/clinical-library.../aospine-injury-classification-system>

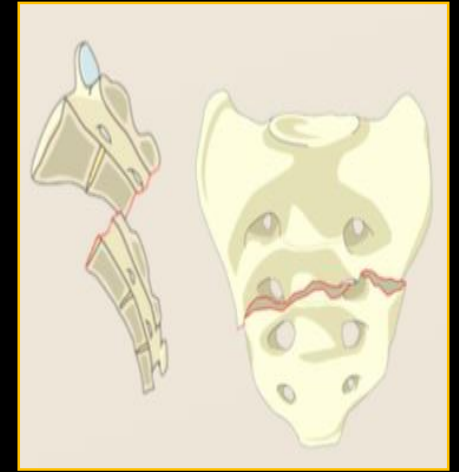
2. Sacral Fractures: Classification & management; Beckmann NM, Chinapuvvula NR, Emerg Radiology, 2017 Oct.

# Type A: Lower Sacrococcygeal Fractures

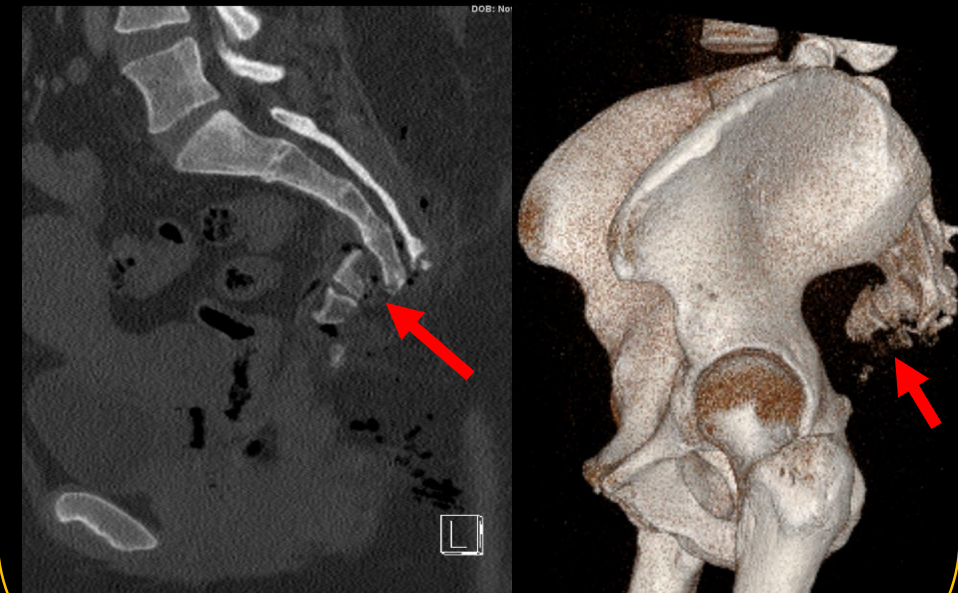
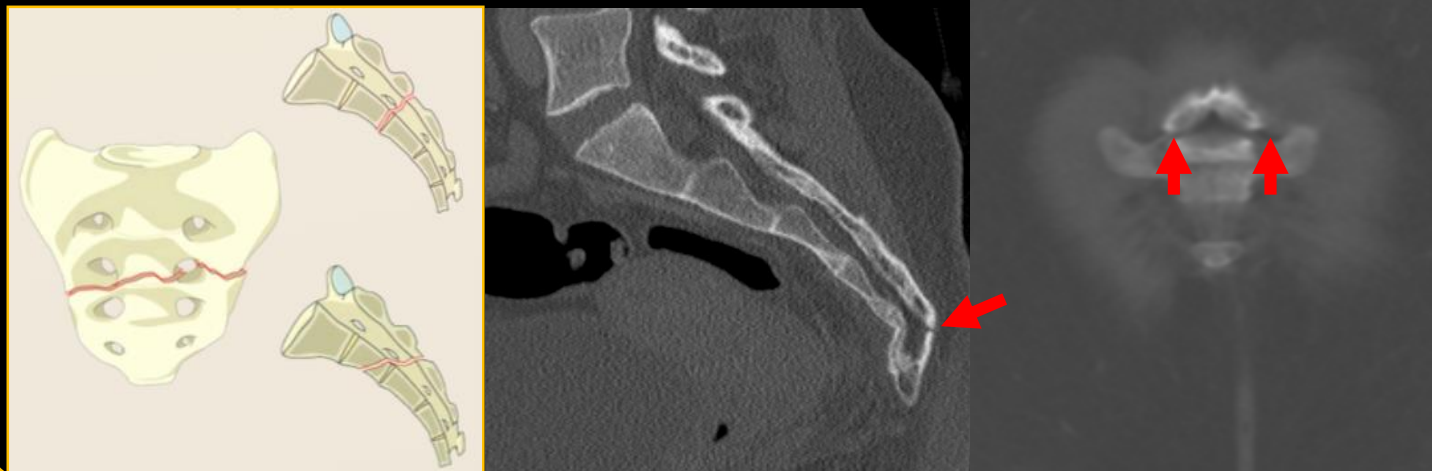## A1: Coccygeal/compression/ligamentous avulsion



## A3: Displaced transverse fractures below the SI joint



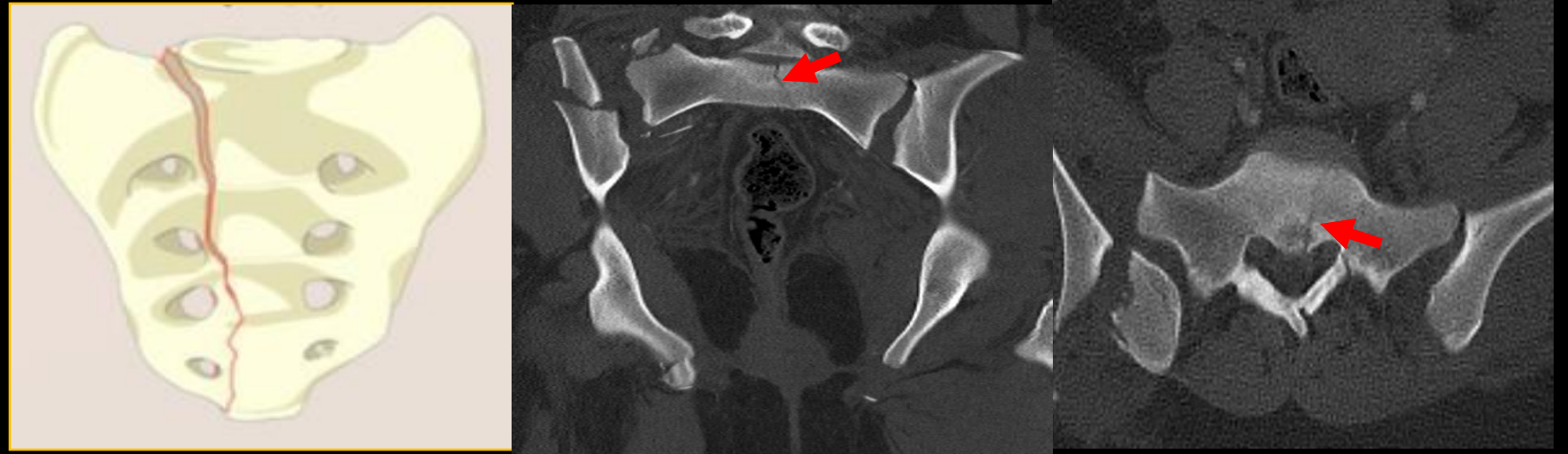## A2: Nondisplaced transverse Fx below the SI joint



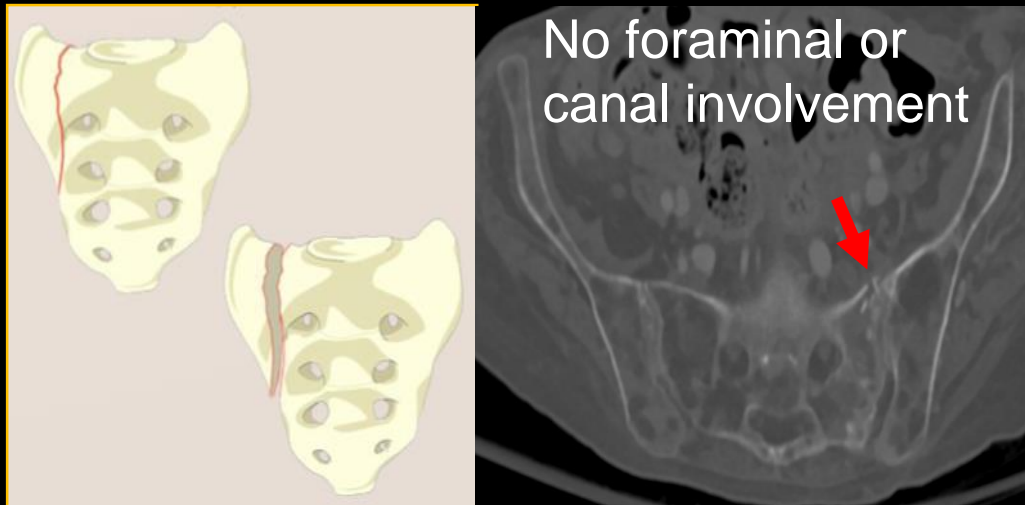
# Type B- Posterior Pelvic Fractures

## B1:

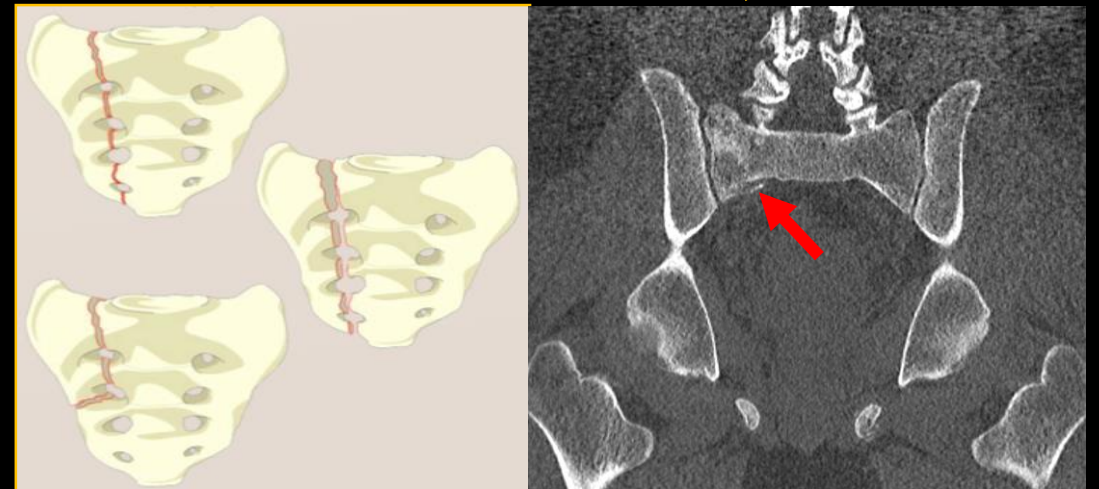
- Central fracture, involves spinal canal
- Denis Zone III



## B2: Transalar fracture, Denis Zone 1

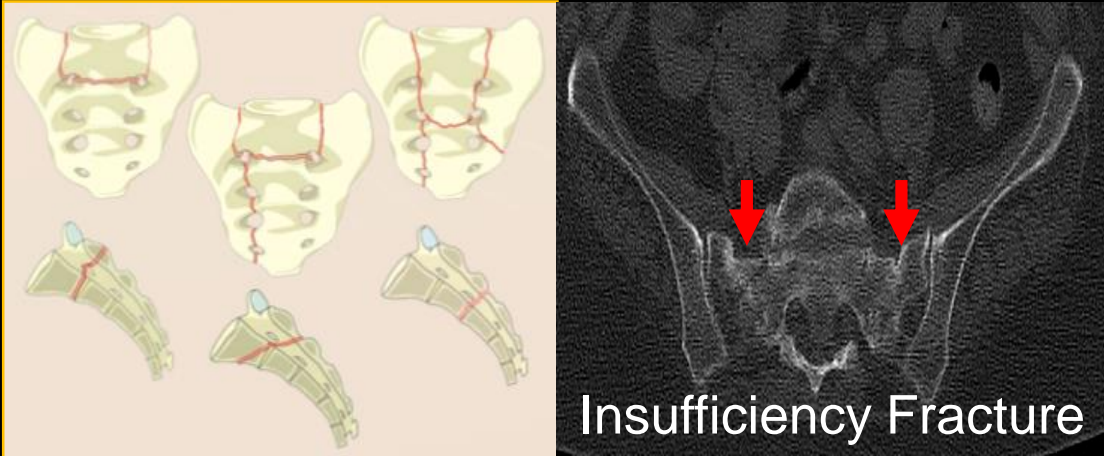


## B3: Transforaminal fracture, Denis Zone II

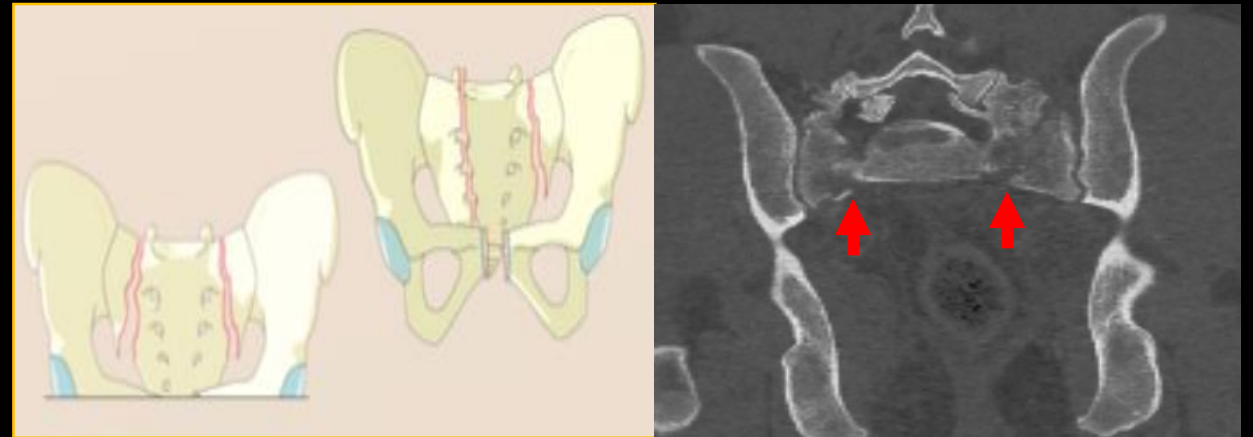

# Type C: Spinopelvic Fractures

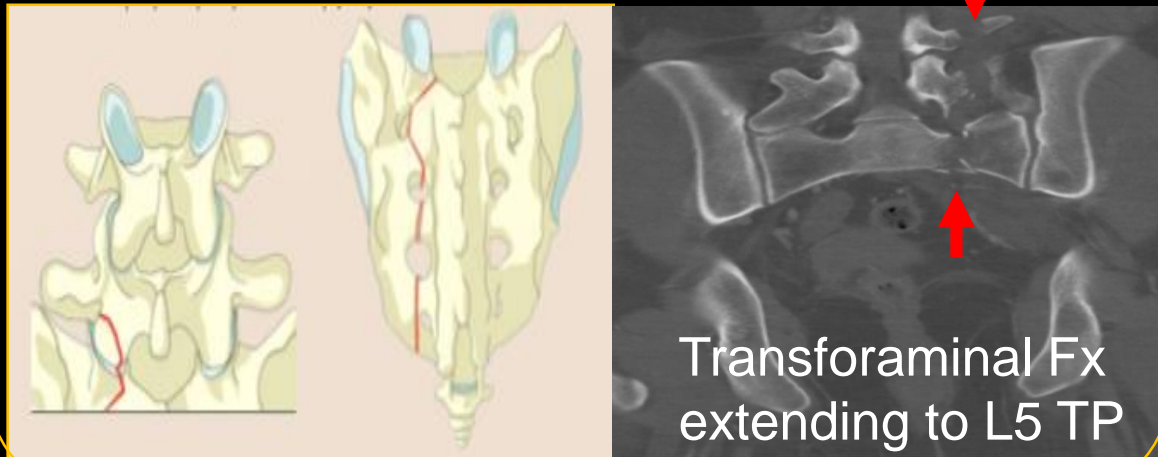
C0: Nondisplaced sacral U-type variant



C2: B/L Type B injuries without transverse fracture



C1: Alternative Sacral U-type variant without posterior pelvic instability



C3: Displaced U-type fracture

